

Interventional Treatment of Severe Tricuspid Regurgitation Early Clinical Experience in a Multicenter, Observational, First-in-Man Study

Alexander Lauten, MD; Hans R. Figulla, MD; Axel Unbehaun, MD; Neil Fam, MD;
Joachim Schofer, MD; Torsten Doenst, MD; Joerg Hausleiter, MD; Marcus Franz, MD;
Christian Jung, MD, PhD; Henryk Dreger, MD; David Leistner, MD; Brunilda Alushi, MD;
Anja Stundl, MD; Ulf Landmesser, MD; Volkmar Falk, MD; Karl Stangl, MD; Michael Laule, MD

Background—Transcatheter caval valve implantation is under evaluation as a treatment option for inoperable patients with severe tricuspid regurgitation (TR). The procedure involves the catheter-based implantation of bioprosthetic valves in the inferior vena cava and superior vena cava to treat symptoms associated with TR. This study is the first to evaluate the feasibility, safety, and efficacy of this interventional concept.

Methods and Results—Twenty-five patients (mean age, 73.9±7.6 years; women, 52.0%) with severe symptomatic TR despite optimal medical treatment deemed unsuitable for surgery were treated with caval valve implantation under a compassionate clinical use program. Technical feasibility defined as procedural success, hemodynamic effect defined as venous pressure reduction, and safety defined as periprocedural adverse events were evaluated, with clinical follow-up at discharge and up to 12 months. The functional impact was evaluated by assessment of New York Heart Association class at the time of hospital discharge. The total number of valves implanted in the caval position was 31. Patients were treated with single (inferior vena cava-only; n=19; 76.0%) or bicaval valve implantation (inferior vena cava+superior vena cava; n=6; 24.0%). Either balloon-expandable valves (Sapien XT/3; n=18; 72.0%) or self-expandable valves (TricValve; n=6; 24.0%; Directflow; n=1; 4.0%) were used. Procedural success was achieved in 96% (n=24). Early and late valve migration requiring surgical intervention occurred in 1 patient each. Thirty-day and in-hospital mortality were 8% (2 of 25) and 16% (4 of 25). Causes of in-hospital mortality included respiratory (n=1) or multiple organ failure (n=3) and were not linked to the procedure. Mean overall survival in the study cohort was 316±453 days (14–1540 days).

Conclusions—Caval valve implantation for the treatment of severe TR and advanced right ventricular failure is associated with a high procedural success rate and seems safe and feasible in an excessive-risk cohort. The study demonstrates hemodynamic efficacy with consistent elimination of TR-associated venous backflow and initial clinical improvement. These results encourage further trials to determine which patients benefit most from this interventional approach. (*Circ Cardiovasc Interv.* 2018;11:e006061. DOI: 10.1161/CIRCINTERVENTIONS.117.006061.)

Key Words: heart valve prosthesis implantation ■ hemodynamics ■ tricuspid regurgitation
■ tricuspid valve insufficiency ■ vena cava, superior

Severe tricuspid regurgitation (TR) is a complex condition of the right ventricle (RV) and tricuspid valve apparatus and is frequently associated with symptomatic heart failure and a significant morbidity and mortality.^{1,2} In these patients, left heart pathologies lead to chronic pressure overload of the RV, eventually causing progressive RV dilatation and functional TR.^{3–6}

In patients with severe TR, medical therapy restricted to diuretics and heart failure medication is frequently ineffective, and surgical repair is associated with a high risk of morbidity and mortality.^{7–10} Furthermore, neither one of these treatment options has demonstrated beneficial long-term effects. Therefore, multiple innovative interventional treatment concepts to replace or repair tricuspid valve function are currently under investigation.^{11–18} However, up to date, none of these approaches is established, and there is

See Editorial by O'Neill

Received October 11, 2017; accepted December 18, 2017.

From the Charité – Universitätsmedizin Berlin, Germany (A.L., H.D., D.L., B.A., U.L., K.S., M.L., V.F.); Deutsches Zentrum für Herz-Kreislauf-Forschung (DZHK), Berlin, Germany (A.L., H.D., D.L., B.A., U.L., K.S., M.L., A.U., V.F.); Friedrich-Schiller-Universität Jena, Germany (H.R.F., T.D., M.F.); Department of Medicine II, Heart Center Bonn, University Hospital Bonn, Germany (A.S.); German Heart Center Berlin (A.U., V.F.); Division of Cardiology, St. Michaels Hospital, Toronto, Canada (N.F.); Albertinen Heart Center, Hamburg, Germany (J.S.); Medizinische Klinik und Poliklinik I, Ludwig-Maximilians-Universität München, Munich, Germany (J.H.); Medical Faculty, Division of Cardiology, Pulmonology and Vascular Medicine, University Düsseldorf, Germany (C.J.); and Berlin Institute of Health, Germany (U.L.).

The Data Supplement is available at <http://circinterventions.ahajournals.org/lookup/suppl/doi:10.1161/CIRCINTERVENTIONS.117.006061/-DC1>.

Correspondence to Alexander Lauten, MD, Charité – Universitätsmedizin Berlin, Charité Campus Mitte and Campus Benjamin Franklin, Berlin, Germany. E-mail alexander.lauten@charite.de

© 2018 American Heart Association, Inc.

Circ Cardiovasc Interv is available at <http://circinterventions.ahajournals.org>

DOI: 10.1161/CIRCINTERVENTIONS.117.006061

WHAT IS KNOWN

- Multiple concepts for transcatheter treatment of severe tricuspid regurgitation are currently under investigation.
- Despite the increasing application of these techniques, there is a lack of data on feasibility, safety, and efficacy of these treatment approaches.

WHAT THE STUDY ADDS

- Herein, we summarize the current experience with caval valve implantation in 25 compassionate patients undergoing inferior vena cava-only or bicaval valve implantation using either balloon- or dedicated self-expandable valves.
- As observed in this study, the caval valve implantation technique is feasible and hemodynamically effective and reproducibly results in the reduction of caval backflow in selected patients.
- As observed in the present study, this hemodynamic improvement may potentially translate into clinical improvement.

still a lack of clinical data to support the efficacy of transcatheter TR treatment.

Transcatheter caval valve implantation (CAVI) has been suggested as one of these interventional concepts.^{19,20} In the pathological cascade of tricuspid valve disease, CAVI aims at the resolution of caval backflow that occurs at a late stage of severe TR. Multiple cardiovascular centers have, therefore, performed CAVI as compassionate treatment only in highly symptomatic patients with multiple advanced comorbidities.^{21–23} Herein, we report the procedural safety, efficacy, and clinical outcome of 25 patients treated with the CAVI approach for severe TR.

Methods

Study Design and Collection of Data

A total of 25 patients considered unsuitable for surgery on decision by local heart teams were included in this study and treated under a compassionate clinical use program. Patients presenting with symptomatic TR despite optimal medical treatment were considered for this approach and recruited from 6 tertiary cardiovascular centers located in Germany and Canada. Because of the limited availability of devices, the period of treatment covered 6 years beginning March 2010 to February 2017. Data were collected at each site using a standardized case report form to record demographic and clinical characteristics and procedural and follow-up data. Follow-up was obtained at the time of discharge and at 12 months based on either physician or patient interviews and medical records. The investigators had full access to the data and control of the data analysis. All patients provided informed consent, and treatment was performed after institutional review board approval. The study was approved by the Ethics Committee of the Charité—Universitätsmedizin Berlin. The study materials cannot be made publically available to other researchers because none of these dedicated interventional devices are available for regular clinical use yet.

Patient Screening and Follow-Up

Before treatment, patients underwent screening for anatomic and hemodynamic suitability. To evaluate hemodynamic suitability, right

heart catheterization was performed to confirm severity of TR, as well as caval backflow confirmed by the presence of a large ventricular (v-) wave in the right atrium (RA), the superior vena cava (SVC), and the inferior vena cava (IVC) location. Patients with a systolic pulmonary artery pressure >60 mmHg or a massively depressed tricuspid annular plane systolic extension (TAPSE <10 mm) function were excluded. To evaluate anatomic suitability, a computed tomographic angiogram was obtained to assess the anatomy and diameter of the device landing zones in the IVC and SVC at the cavoatrial junction.

Anatomic screening and decision for single versus bicaval implantation depended on the available devices. For implantation of balloon-expandable valves (BEV), an IVC diameter at the diaphragmatic intersection and an SVC diameter at the atrial inflow of ≤30 mm were considered suitable for valve implantation. Furthermore, a tapered anatomy or severe venous elongation of the SVC at the designated landing zone was considered as unsuitable. Anatomic exclusion criteria for TricValve implantation included an IVC diameter at the diaphragmatic intersection and an SVC diameter at the SVC right pulmonary artery crossing of >35 mm.

Implantation Procedure and Devices

Procedural success was defined as successful valve delivery and deployment at the designated landing zone. The procedures were performed under general anesthesia with fluoroscopic and transesophageal echo guidance. Unfractionated heparin was administered to reach an activating clotting time >250 seconds throughout the procedure. The hemodynamic impact was evaluated during the procedure using invasive pressure tracings in the RA and IVC, as well as cardiac output measurements. After the procedure, venous closure was achieved by either the use of percutaneous closure devices or a so-called Z-suture of the skin. Patients were monitored in the intensive or intermediate care unit and discharged home or to a rehabilitation program based on clinical requirements. Anticoagulation was afforded using vitamin K antagonists (eg, phenprocoumon) in all patients.

CAVI Using BEV

The Edwards Sapien BEV have been described previously in detail. Because of the commercial availability of the Edwards Sapien XT and Sapien 3 valves for treatment of aortic stenosis (29-mm Edwards Sapien XT or Sapien 3; Edwards Lifesciences, Irvine, CA), there is a growing experience in the off-label use of these devices for treating severe TR. Although the use of BEV has been commonly limited to the IVC, in selected cases, the long segment of the SVC facilitates BEV implantation using the same implant technique if needed. The anatomy of the cavoatrial junction of the IVC (particularly the large diameter, the inflow of hepatic veins, and the compliance of the venous wall) precludes direct implantation of a BEV and requires the preparation of a landing zone by implanting a self-expandable stent to facilitate valve fixation.

The procedure is performed using fluoroscopy through the right femoral vein. After placement of the 6F sheath, a stiff wire is placed in the SVC and a 16F (for S3) or 20F (for ES XT) sheath advanced below the diaphragm. A self-expandable stent tailored to IVC diameter (eg, 30×80 mm) is implanted in the IVC at the level of the diaphragm and protruding ≈5 mm into the RA. The 29-mm BEV mounted on the delivery system is then deployed inside the stent with the lower part just superior to the confluence of the first hepatic vein (Figure 1). For a bicaval valve implantation (BiCAVI) procedure, a self-expanding stent is deployed in the SVC above the RA inflow (to reduce the risk of vessel wall damage and rupture) and the SVC prosthesis implanted in the same manner.

CAVI Using Self-Expandable TricValve

The TricValve (P&F, Vienna, Austria) is designed as a set of 2 self-expandable valves specifically for SVC and IVC implantation in the low pressure circulation. The SVC valve is a belly-shaped tapered device for anchoring in dilated, tapered SVC configuration. The IVC valve is deployed at the level of the diaphragm and protruding into the RA. Both devices are made of bovine pericardium, and the inner part of the atrial stent portion is lined with a polytetrafluorethylene skirt.

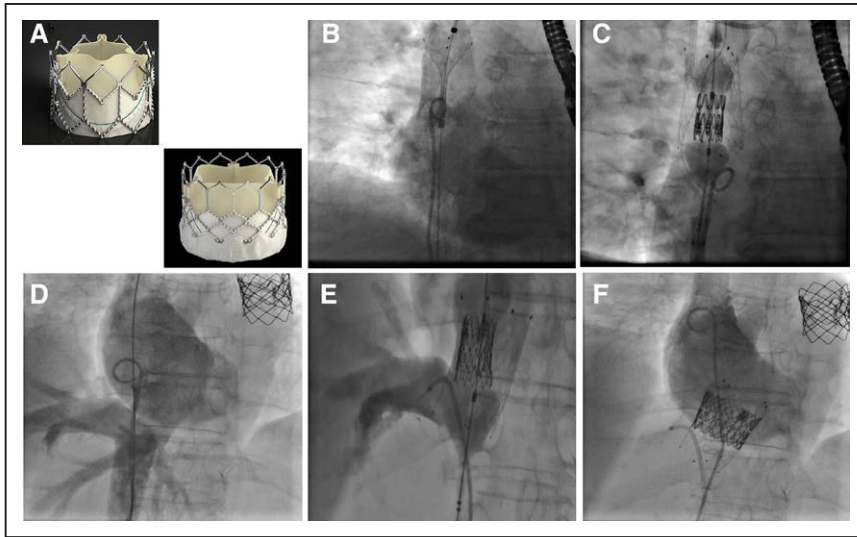


Figure 1. Caval valve implantation using balloon-expandable valves (BEV). **A**, Edwards Sapien XT and Edwards Sapien 3 BEV have been used for CAVI. **B** and **C**, BEV-in-superior vena cava (SVC) implantation requires favorable anatomy. After pre-stenting with a self-expandable stent, a 29-mm BEV is deployed within in the stented SVC segment without right atrium (RA) protrusion. **D**, Right atrial angiogram is performed with contrasting of the inferior vena cava (IVC) demonstrating severe tricuspid regurgitation. **E** and **F**, A self-expandable stent is in the IVC-RA junction with ≈ 2 cm RA protrusion. After positioning of a Judkins Right catheter marking hepatic vein inflow, the 29-mm BEV is deployed within the stent at level of the diaphragm.

For implantation, an Amplatz wire with a long soft J-tip is advanced through the right femoral vein and the RA into the right internal jugular vein. Both devices are loaded into 27F catheters for sheathless implantation. Before SVC valve implantation, a catheter is placed distally in the right pulmonary artery as marker of the IVC-right pulmonary artery crossing. The SVC valve is then deployed with the landing zone of the enlarged midportion of the stent above the right pulmonary artery. The IVC valve is deployed with the upper, skirt-lined segment of the stent protruding into the RA, and the device fully anchored in the IVC. The constrained segment of the stent should be aligned with the cavoatrial junction by careful pullback of the catheter to avoid occlusion of hepatic vein inflow just below the diaphragm. With a safety margin of 5 mm, care was taken to avoid a low or high valve position causing either hepatic vein obstruction or paravalvular

regurgitation (Figure 2). All procedures were fluoroscopy and transesophageal echocardiography guided (implantation procedure and echo—Movie in the [Data Supplement](#)).

Statistics

Continuous data are presented as mean \pm SD, and categorical variables are depicted as percentages and numbers. Statistical testing was performed with a paired *t* test for continuous variables if distributed normally, otherwise exact testing was performed. The Wilcoxon signed-rank test was used for categorical variables. A $P < 0.05$ was considered statistically significant. Kruskal-Wallis test or χ^2 was used for intergroup comparisons. All statistical analyses were performed using the SPSS statistical package, version 23.0 (IBM Corp, New York, NY).

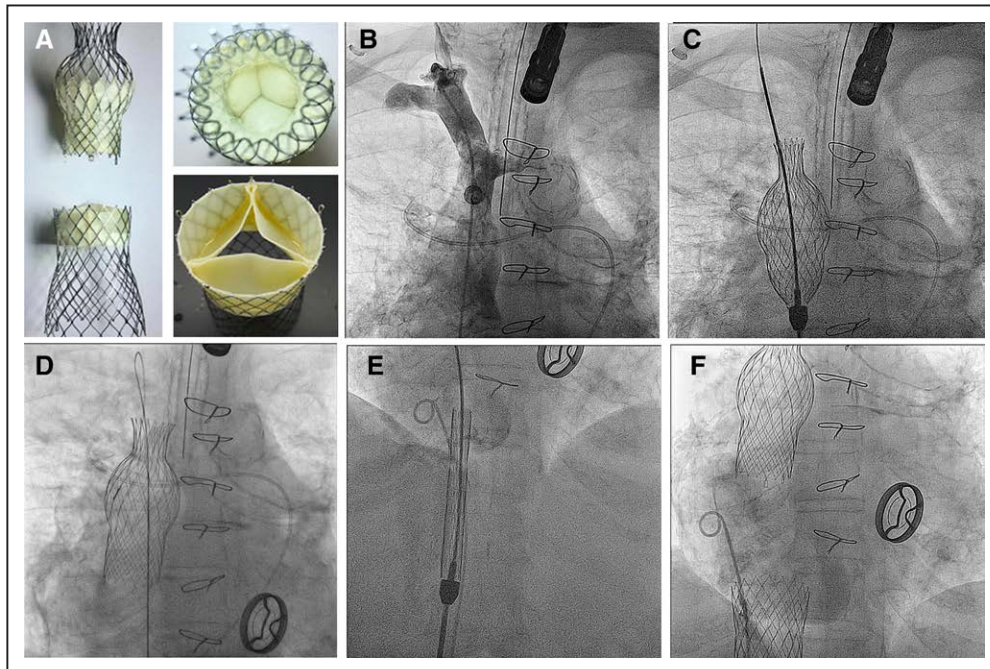


Figure 2. Caval valve implantation (CAVI) using self-expandable valves (SEV; TricValve). **A**, The TricValve SEV, an investigational device with 2 designated valves for superior vena cava (SVC) and inferior vena cava (IVC) position, has been used for CAVI. **B** and **C**, An angiogram of the right subclavian vein and SVC is obtained. A catheter marks the position of the right pulmonary artery. **D** and **E**, The device is deployed above the IVC-right pulmonary artery crossing with the distal end at the level of the inflow of the left brachiocephalic vein. **E** and **F**, The IVC valve is advanced into the right atrium (RA) in a 27F catheter and aligned with the distal valve segment ≈ 2 cm above the diaphragm protruding into the RA.

Results

Patients and Baseline Characteristics

Patients (n=25; women, 52%; age, 73.9±0.7.6 years; EuroScore II, 18.2±12.9; Society of Thoracic Surgeons (STS) mortality score, 14.0±12.7) with massive TR and symptoms of right heart failure were considered for this novel treatment approach under a compassionate clinical use program. The majority of patients had a history of previous cardiac surgery (n=19; 76%), including 6 patients (24%) with ≥2 preceding open heart surgical procedures or aortic replacement because of aortic dissection and 1 patient after heart transplantation. Five (20%) patients had had previous transcatheter valve procedures, including transcatheter aortic valve implantation (n=1), transcatheter pulmonary valve (n=2), or MitraClip procedure (n=2).

A significant proportion of patients experienced progressive cancer (n=7; 28%). Thirty-six percent (n=9) had permanent pacemaker leads positioned in the SVC across the tricuspid annulus. The indication for CAVI was made on decision of local heart teams in nonsurgical patients with persistent and debilitating symptoms of heart failure despite optimal medical therapy. Clinical exclusion criteria included a limited life expectancy <3 month, severely depressed RV function (TAPSE <10 mm), and a systolic pulmonary artery pressure >60 mm Hg.

At baseline, 72% (n=18) and 28% (n=7) of patients were in New York Heart Association (NYHA) class IV and III, respectively. Plasma NT-proBNP (N-terminal pro-B-type natriuretic peptide) levels were markedly elevated at 3016 pg/mL (765–5588 pg/mL; Table 1).

Baseline echocardiography showed an impaired ejection fraction <50% in 40% (average ejection fraction, 51.0±15.0%), and an impaired RV function with TAPSE <16 mm was observed in 32% (n=10; average TAPSE, 13.0±1.83 mm). Functional TR was present in 96% (n=24) and structural (rheumatic) TR in 4% (n=1) of patients, respectively. Systolic pulmonary artery pressure was moderately increased at baseline (41.0±13.9 mm Hg), and all patients with pulmonary arterial hypertension were in group 2 according to the 2013 Nice classification.²⁴

Procedural Results

The total number of valves implanted within this study was 31. Patients were treated with single valve implantation (IVC-only; n=19; 76.0%) or BiCAVI (IVC and SVC; n=6; 24.0%). In these patients, either balloon-expandable valves (Sapien XT or Sapien 3; n=17; 78.3%) or self-expandable valves (TricValve; n=7; 21.7%; Directflow; n=1; 4.0%) were used for either single IVC or BiCAVI. One patient was treated by IVC-only implantation of a direct flow medical valve prosthesis (Direct Flow Medical, Santa Rosa), a nonmetallic device with an inflatable and deflatable support structure (Figure 3). Ninety-six percent of devices were implanted through femoral venous access and 1 implantation (Directflow) via right internal jugular access. When BEV were used, different techniques of IVC landing zone preparation and downsizing were required, such as pre-stenting with ≥1 self-expandable stents (n=16) or surgical banding (n=2), depending on local heart team decision.

Table 1. Patient Demographics and Comorbidities

Patient Demographics	Mean±SD and Range or n (%)
Age (mean±SD)	73.9±7.6
Female, n (%)	13 (52)
EuroScore II	18.2±12.9; 5.1–54.2
STS Score (MVR)*	14.0±12.7; 1.6–42.3
NYHA III	7 (28)
NYHA IV	18 (72)
NT-proBNP	3028 (765–12538)
Left ventricular ejection fraction (EF, %)	51±15 (15–74)
Pathogenesis of TR	
Functional	24 (96)
Structural (rheumatic)	1 (4)
Diabetes mellitus, n (%)	11 (44.0)
Hypertension, n (%)	23 (92.0)
Coronary artery disease, n (%)	12 (52.0)
Percutaneous coronary intervention	7 (28)
Previous myocardial infarction	8 (32)
Previous cardiac surgery, n (%)	19 (76.0)
Permanent pacemaker or ICD, n (%)	9 (36.0)
Stroke or TIA, n (%)	2 (8.0)
End-stage renal failure, dialysis, n (%)	11 (44.0)
Glomerular filtration rate, mL/min	35.3±17.9
COPD, n (%)	8 (32.0)
Peripheral vascular disease, n (%)	4 (16.0)
Cancer, n (%)	7 (28.0)
Requirement for oral anticoagulation	25 (100)

COPD indicates chronic obstructive pulmonary disease; ICD, implantable cardioverter defibrillator; MVR, mitral valve replacement; NYHA, New York Heart Association; NT-proBNP, N-terminal pro-B-type natriuretic peptide; STS, Society of Thoracic Surgeons; TIA, transient ischemic attack; and TR, tricuspid regurgitation.

*As the STS score is undefined for tricuspid procedures, values are calculated for MVR.

Intraprocedural and In-Hospital Safety Data

Procedural success (defined as successful delivery of 1 or 2 valves in intended position) was achieved in 92% of cases. There were no intraprocedural deaths. However, in one case, conversion to open heart surgery was required after migration of an SVC prosthesis within minutes after deployment. In another case, an IVC prosthesis migrated from the stent into the RA within the first 30 days. In both cases, the prosthetic valves were surgically recovered from the RV. No other serious events, including stroke, myocardial infarction, pericardial effusion, or vascular complications, occurred (Table 2).

Peri- and Postprocedural Hemodynamics and Echocardiography

In all patients, CAVI resulted in a complete reduction of reverse caval flow. This was confirmed by a significant reduction of the

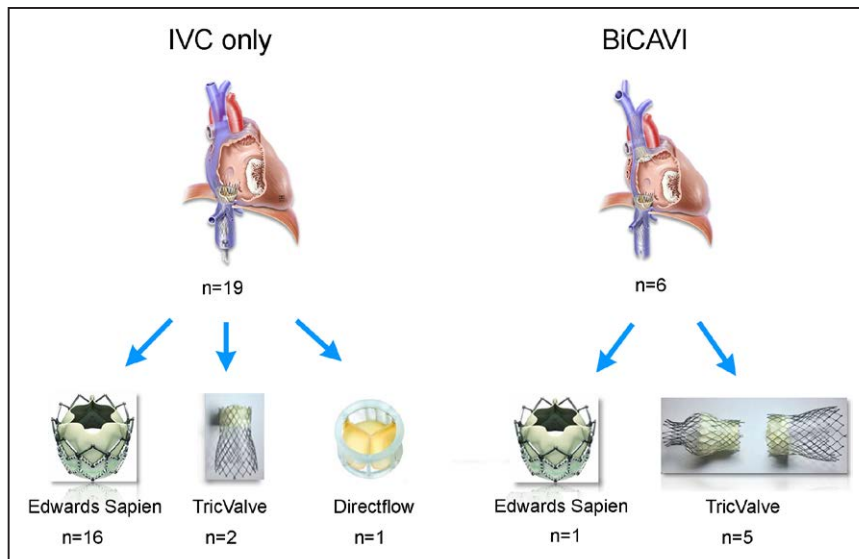


Figure 3. Procedural characteristics. The total number of valves implanted within this study was 31. Patients were treated with single valve implantation (n=19; 76.0%) or bicaval valve implantation (n=6; 24.0%). Balloon-expandable valves (Sapien XT or Sapien 3: n=17; 78.3%) or self-expandable valves (TricValve: n=7; 21.7%; Directflow: n=1; 4.0%) were used for either single inferior vena cava (IVC) or bicaval valve implantation (BiCAVI). One case was treated by IVC-only implantation of a direct flow medical valve prosthesis (Direct Flow Medical, Santa Rosa). When self-expandable valves were used, different techniques of IVC landing zone preparation and downsizing were required, such as pre-stenting with ≥ 1 self-expandable stents (n=16) or surgical banding (n=2), depending on local heart team decision.

IVC v-wave and mean pressure from 31.4 ± 6.4 and 21.7 ± 4.3 mmHg to 21.1 ± 4.5 mmHg ($P < 0.0001$) and 17.6 ± 3.3 mmHg ($P = 0.01$), respectively. In the RA, mean pressure decreased from 21.2 ± 6.0 to 17.6 ± 3.3 mmHg immediately after implantation, whereas the v-wave acutely increased from 29.5 ± 7.1 to 35.5 ± 13.1 mmHg ($P = 0.07$; Table 3). Cardiac index, determined either by oximetry or noninvasive echocardiographic measurement, increased nonsignificantly from 2.5 ± 0.7 to 2.8 ± 0.9 L/min per m^2 ($P = 0.76$).

At baseline, mean TAPSE was 16.5 ± 4.1 and remained unchanged after the procedure (16.5 ± 4.9 mm; $P = 0.95$). In patients with depressed RV function (TAPSE < 16 mm) at baseline (n=10), TAPSE improved nonsignificantly from 13.0 ± 1.83 to 13.7 ± 2.95 ($P = 0.41$). RV area and tricuspid annulus remained unchanged (RA area: 64.9 ± 54.4 versus 63.8 ± 50.2 cm^2 ; $P = 0.94$; tricuspid valve annulus: 51.0 ± 6.7 versus 50.4 ± 7.8 mm; $P = 0.76$). Intact valve function was observed in all implanted devices during follow-up (Figure 4).

Postoperative Clinical Course and Clinical Follow-Up

Thirty-day mortality was 12% (n=3; Table 2). These patients died from progressive multiorgan failure and septic complications 6, 14, and 24 days after the intervention. In-hospital mortality was 24% (n=6). Two patients developed pneumonia and died from respiratory failure day 34 and day 41 after implantation and 1 patient died from multiple organ failure 45 days after implantation.

Mean follow-up time after the procedure was 316 ± 453 days (14–1540 days) after CAVI. In all patients discharged alive from hospital (n=19), transthoracic echocardiography obtained during follow-up confirmed appropriate function of all implanted devices. Longest follow-up of 51 month is available for a BiCAVI patient with documented intact valve function. Before the procedure, 72% of patients were in NYHA class IV. In patients discharged from hospital (n=19), symptoms improved in 84.2% (n=16) by ≥ 1 NYHA class. At the time of discharge, 9 patients remained in NYHA class III or IV (47.3%) and 52.7% improved to NYHA class I or II (Figure 5).

Plasma NT-proBNP levels were markedly elevated at baseline and increased nonsignificantly within 30 days after the procedure (NT-proBNP: 3028 pg/mL [765–12 538 pg/mL] versus 10 711 [6510–23 054] /mL; $P = 0.015$).

Table 2. Procedural, Safety, and In-Hospital Data

	n (%)
No. of patients	25 (100)
No. of valves implanted	31 (100)
IVC-only (devices)	19 (61.3)
ES XT or ES 3	16
TricValve	2
Directflow Medical	1
BiCAVI (devices)	12 (38.7)
ES XT	2
TricValve	10
Immediate procedural success	23/25 (92)
Device embolization	2/25 (8)
Conversion to surgery	1/25 (4)
Vascular complications	0 (0)
Bleeding complications other than access site	3/25 (12)
New permanent pacemaker	0 (0)
Stroke	0/25 (0)
New onset renal failure (requiring dialysis)	0/14 (0)
NYHA improvement	13/18 (72)
Mortality	
30 d	3/25 (12%)
In-hospital	6/25 (24%)
12 mo	14/22 (63%)*
Mean long-term follow-up, d	316 ± 453 ; (6–1540)

BiCAVI indicates bicaval valve implantation; and IVC, inferior vena cava.

*Twelve-month follow-up complete for n=22 patients only. Three patients were implanted < 12 months.

Table 3. Changes in Hemodynamic, Echocardiographic, and Clinical Variables Between Baseline and Follow-Up

	Baseline	Post-CAVI	P Value
Hemodynamics*			
Right atrial pressure			
Mean, mm Hg	21.2±6.0	17.0±3.9	0.02
v-wave, mm Hg	29.5±7.1	35.5±13.1	0.07
IVC pressure			
Mean, mm Hg	21.7±4.3	17.6±3.3	0.01
v-wave, mm Hg	31.4±6.4	21.1±4.5	<0.0001
Mean PA pressure, mm Hg	26.0±7.7	27.3±11.5	0.57
Cardiac index, L/min per m ²	2.5±0.7	2.8±0.9	0.76
Echocardiographic variables†			
Right atrial area, cm ²	64.9±54.4 39.5 (29.1–91.0)	43.0 (28.0–93.5)	0.6
TAPSE, mm	16.5±4.1	16.5±4.9	0.95
TAPSE <16 mm (n=10)	13.0±1.83	13.7±2.95	0.41
Tricuspid annulus	51.0±6.7	50.4±7.8	0.76
Laboratory and clinical follow-up†			
Creatinine‡	1.4±0.27	1.6±0.34	0.02
Body weight, kg	78.1±11.6	74.1±9.3	0.025
NYHA class (n=19)			<0.0001
IV	63.2 (12)	10.5 (2)	
III	36.8 (7)	36.8 (7)	
II	0	42.2 (8)	
I	0	10.5 (2)	

IVC indicates inferior vena cava; NYHA, New York Heart Association; PA, pulmonary artery; and TAPSE, tricuspid annular plane systolic extension.

*Obtained during the implantation procedure.

†At baseline and before discharge.

‡Values presented for nondialysis patients only.

Discussion

Because medical therapy is often ineffective for long-term treatment of symptoms associated with severe TR, interventional treatment approaches are gaining increasing attention, and several catheter-based approaches and dedicated devices are currently under investigation.^{13,14} These interventional strategies are frequently adopted from the mitral space, including concepts, such as leaflet approximation, coaptation enhancement, or direct and indirect annuloplasty.^{11,17,25–28} All of these concepts and devices are in early stages of clinical development with experience limited to patient series and follow-up of weeks to month at best. In this developing and innovative field, the optimal concept remains a matter of debate.

Herein, we describe the currently used techniques and devices used for CAVI and summarize the available evidence in the largest study cohort treated with this concept. The procedure was first performed in patients in 2010 and was one of the first interventional strategies to be applied for TR treatment.²¹

Since then, multiple institutions have adopted this procedure for compassionate use cases of patients with late-stage TR and associated RV failure. In these patients, TR is most frequently functional in nature and associated with RV dilatation and dysfunction. Structural defects are rare as can be observed by the distribution of TR pathogenesis in the present study.

The CAVI approach primarily aims to resolve backflow into the caval veins and treat associated symptoms of heart failure. In the pathological cascade of TR, caval backflow occurs at an advanced stage of disease, frequently associated with RV and venous dilatation, impaired RV function, and atrial fibrillation. This fact together with the novelty of the approach and the limited availability of devices resulted in the selection of advanced stage patients with severe and frequently life-limiting concomitant comorbidities, frequently undergoing a last-resort treatment approach. In this study, the STS score was 14.0±12.7, 76% of the patients had previously undergone open heart surgery, 44% (n=11) were in end-stage renal failure, and 28% (n=7) experienced concomitant cancer disease. Despite this unfavorable risk profile, immediate procedural success was 96% (n=24), demonstrating the feasibility and safety of the procedure. Conversion to surgery was required in one case after immediate SVC valve migration. A second patient underwent surgery because of IVC valve migration 10 days after implantation. The implantation procedure was associated with no intraprocedural mortality.

Of note, 36% of patients had a permanent pacemaker in place, which is considered as potential contraindication for other TR-dedicated devices. In the current study, the presence of pacemaker or implantable cardioverter defibrillator leads in the SVC did neither impact the CAVI procedure nor did we observe an effect of the implanted devices on pacemaker or implantable cardioverter defibrillator function.

Because of the limited availability of dedicated devices, balloon-expandable transcatheter aortic valve implantation valves are currently most frequently used for CAVI. In the present study, the use of these devices proved feasible and was hemodynamically effective. However, their use is associated with anatomic limitations with regard to anchoring and sizing. As can be observed by the treatment strategy in the present study, BEV were almost exclusively used for IVC implantation. A BEV implantation into the SVC was performed in only one patient after SVC who presented with a lean, nontapered SVC configuration (Figure 1).

In patients with chronic right heart failure and severe TR, the central segment of the SVC is atrialized and frequently develops tapered dilatation, requiring an anchoring strategy in the upper, nondilated part of the superior vein segment—as afforded by the TricValve stent frame. Furthermore, current generations of BEV are available up to 29 mm only and thus frequently undersized for patients with severely dilated caval veins. The use of BEV for CAVI is, therefore, clearly restricted to the IVC-only and should be performed in the SVC-only in after careful anatomic evaluation.

In this excessive-risk study population, 30-day mortality and in-hospital mortality were 8% and 24%, respectively, with patients dying from noncardiovascular causes despite successful treatment of TR.

The study further confirms the hemodynamic and clinical effect of the procedure in patients with severe TR and central

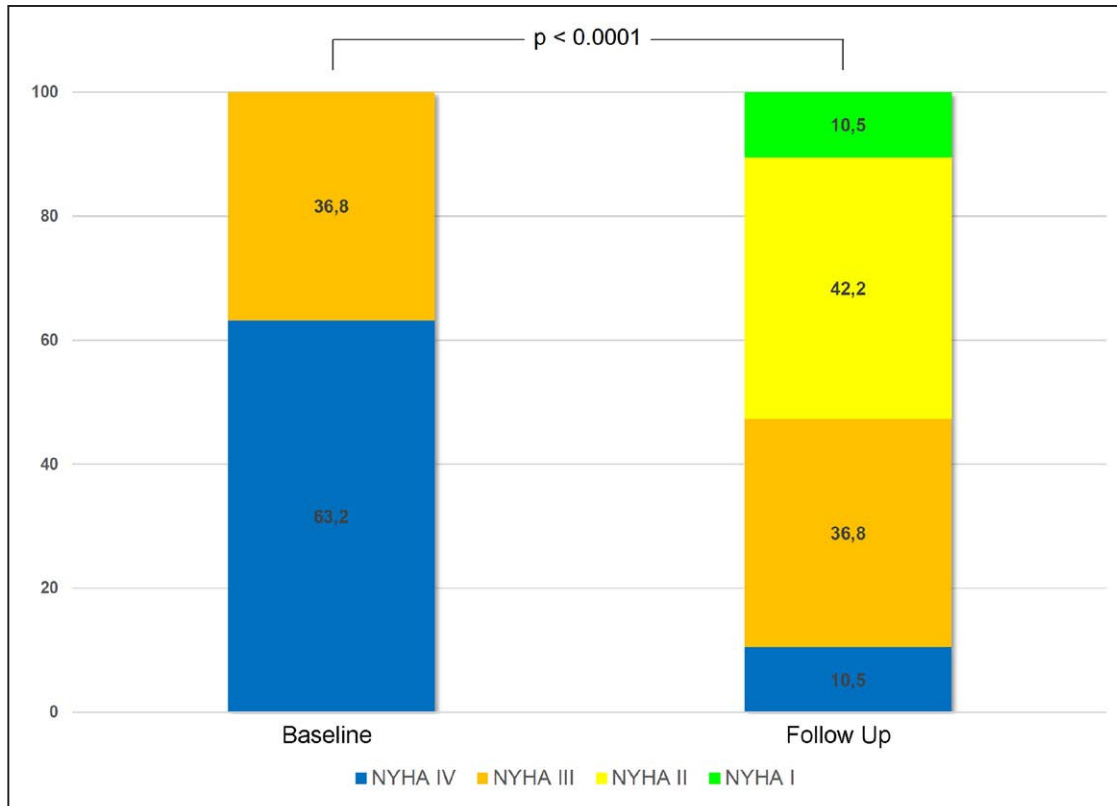


Figure 4. New York Heart Association (NYHA) class change before vs after caval valve implantation in patients discharged from hospital. At baseline, all patients presented in NYHA class III or IV. In patients discharged from hospital ($n=19$), symptoms improved in 84.2% ($n=16$) by ≥ 1 NYHA class. At the time of discharge, 9 patients remained in NYHA class III or IV (47.3%) and 52.7% improved to NYHA class I or II.

venous congestion. Major concerns associated with CAVI include the ventricularization of RA pressure, as well as the persistence of atrial and ventricular volume overload, potentially promoting RV failure and atrial fibrillation. In the present limited human experience, no such deleterious effects were observed. In all patients, the CAVI procedure successfully resolved hemodynamic backflow with a significant reduction of mean pressure in the IVC and the RA from 21.7 ± 4.3 and 21.2 ± 6.0 mmHg to 17.6 ± 3.3 mmHg ($P=0.01$) and 17.0 ± 3.9 mmHg ($P=0.02$), respectively. Despite the immediate increase of the v-wave in the RA from 29.5 ± 7.1 mmHg before the procedure to 35.5 ± 13.1 mmHg ($P=0.07$) after the procedure, echo follow-up suggests neither an increase of RA size (64.9 ± 54.4 versus 63.8 ± 50.2 cm²; $P=0.94$) nor deterioration of RV function (TAPSE 16.5 ± 4.1 versus 16.5 ± 4.9 mm; $P=0.95$). These observations are in line with earlier reports.²⁹

In patients discharged from hospital, CAVI was associated with a symptomatic improvement in 84.2% of patients, with 50.2% of patients improving to NYHA class I or II. Although NT-proBNP values show an upward trend after CAVI, this parameter is likely of limited diagnostic value because of the ventricularization of the RA hemodynamics and the exposition of the RV to a higher afterload after CAVI. Because of the limited number of patients in this study, it is yet unanswered whether bicaval versus single valve implantation has different effects on hemodynamic or clinical outcome. However, this question will be subject of further trials. In the present experience, BiCAVI was performed whenever possible from an anatomic perspective with the available devices.

Although hemodynamically effective, CAVI is in contrast to other interventional procedures because it aims to treat an advanced disease state of central venous regurgitation. In a recent study by Nickenig et al,¹¹ tricuspid edge-to-edge repair using the MitraClip device proved effective to reduce TR severity and improve associated symptoms of heart failure. Although the edge-to-edge technique is an orthotopic treatment concept aiming to restore tricuspid valve function, the technique reduced but did not resolve TR to trace or zero in the majority of patients, which was nevertheless associated with symptomatic improvement.¹¹ The study by Nickenig et al¹¹ included nonsurgical patients as well; however, the patient population presented a more favorable risk profile with less comorbidities. The difference in risk profile is confirmed by an STS score of 4.7 ± 4.6 in the study by Nickenig et al¹¹ versus an STS of 14.0 ± 12.7 in the present study. This finding supports an earlier general observation that patients with severe TR resemble a heterogenic cohort with a wide span of comorbidities, risk profiles, and anatomic specification essentially necessitating a stratified approach for interventional TR treatment.

Limitations

Our exploratory study presents observational data on feasibility of CAVI and summarizes the current experience with this treatment approach. The number of patients is limited, patients were not randomized, and data were acquired without core laboratory adjudication. Because of its exclusive compassionate use, the present clinical experience is currently

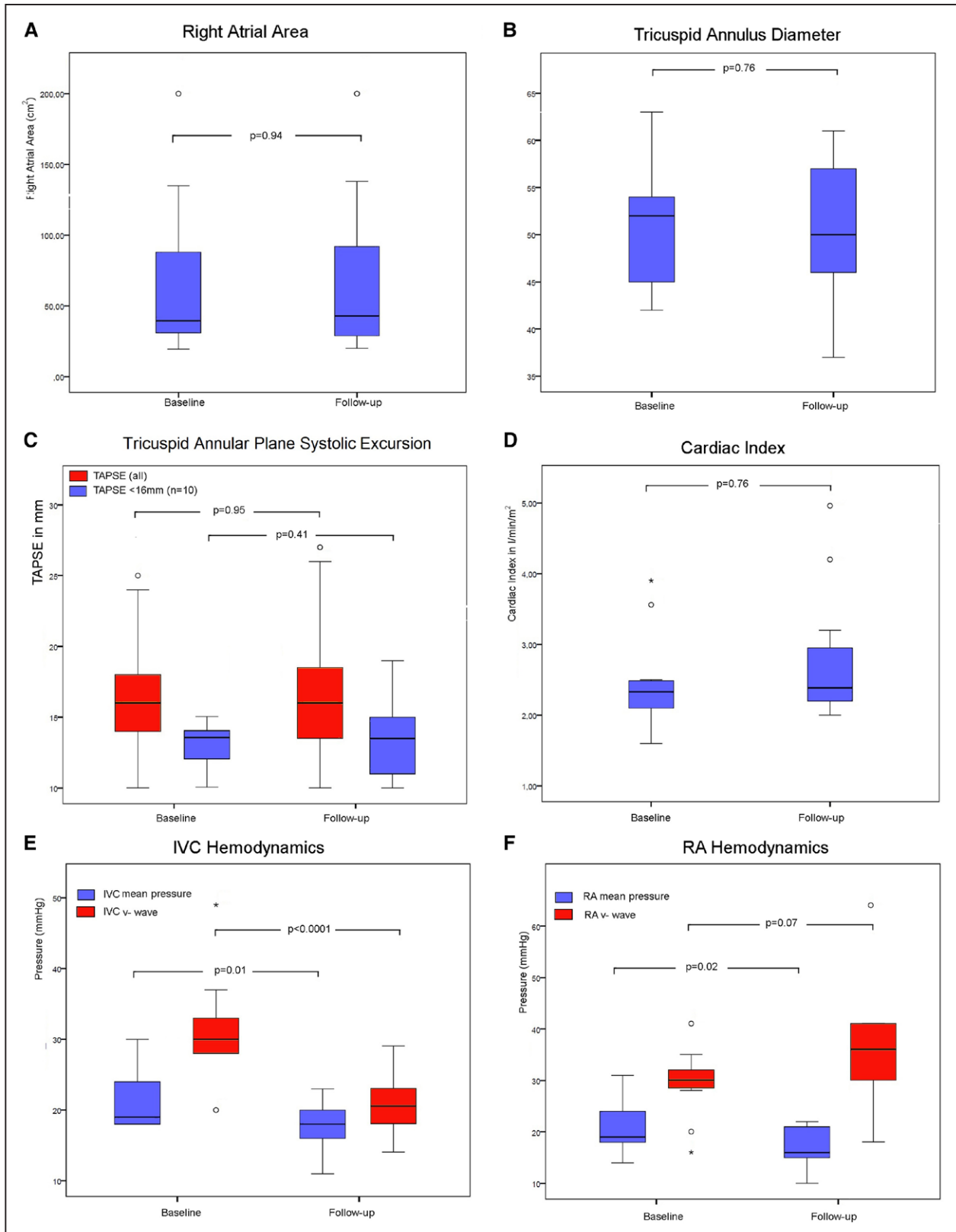


Figure 5. Boxplot diagrams of echocardiographic and hemodynamic changes before vs after implantation. **A–C**, Tricuspid annulus diameter, tricuspid annular plane systolic excursion, and right atrial (RA) area in transthoracic echo before caval valve implantation (CAVI) and before discharge. **D–F**, Cardiac index, mean pressure, and v-wave in the inferior vena cava (IVC) and in the RA before vs immediately after CAVI. °Extreme values. *Statistical outlier. TAPSE indicates tricuspid annular plane systolic extension.

limited to the most severely ill subgroup of patients with limited clinical follow-up. It, therefore, remains unclear whether the presented treatment modality is able to induce a sustained clinical improvement or improve patient prognosis.

Conclusions

Treatment of severe TR and caval backflow with the CAVI technique is feasible and hemodynamically effective. The associated hemodynamic improvement may potentially translate into clinical improvement as observed in the present study. However, further studies, including randomized trials, are necessary to determine which patients benefit most from interventional treatment and to adjust criteria for clinical and anatomic patient selection for different subgroups.

Disclosures

Dr Lauten is a consultant to P&F TricValve and receives research support from Edwards Lifesciences. Dr Figulla is a consultant to P&F TricValve. Drs Stangl and Laule received proctoring fees and research support from Edwards Lifesciences. The other authors report no conflicts.

References

- Nath J, Foster E, Heidenreich PA. Impact of tricuspid regurgitation on long-term survival. *J Am Coll Cardiol*. 2004;43:405–409. doi: 10.1016/j.jacc.2003.09.036.
- Topilsky Y, Nkomo VT, Vatury O, Michelena HI, Letourneau T, Suri RM, Pislaru S, Park S, Mahoney DW, Biner S, Enriquez-Sarano M. Clinical outcome of isolated tricuspid regurgitation. *JACC Cardiovasc Imaging*. 2014;7:1185–1194. doi: 10.1016/j.jcmg.2014.07.018.
- Rogers JH, Bolling SF. The tricuspid valve: current perspective and evolving management of tricuspid regurgitation. *Circulation*. 2009;119:2718–2725. doi: 10.1161/CIRCULATIONAHA.108.842773.
- Dreyfus GD, Corbi PJ, Chan KM, Bahrami T. Secondary tricuspid regurgitation or dilatation: which should be the criteria for surgical repair? *Ann Thorac Surg*. 2005;79:127–132. doi: 10.1016/j.athoracsur.2004.06.057.
- Selle A, Figulla HR, Ferrari M, Rademacher W, Goebel B, Hamadanchi A, Franz M, Schlueter A, Lehmann T, Lauten A. Impact of rapid ventricular pacing during TAVI on microvascular tissue perfusion. *Clin Res Cardiol*. 2014;103:902–911. doi: 10.1007/s00392-014-0728-9.
- Goebel B, Gjesdal O, Kottke D, Otto S, Jung C, Lauten A, Figulla HR, Edvardsen T, Poerner TC. Detection of irregular patterns of myocardial contraction in patients with hypertensive heart disease: a two-dimensional ultrasound speckle tracking study. *J Hypertens*. 2011;29:2255–2264. doi: 10.1097/HJH.0b013e32834bdd09.
- Taramasso M, Vanermen H, Maisano F, Guidotti A, La Canna G, Alfieri O. The growing clinical importance of secondary tricuspid regurgitation. *J Am Coll Cardiol*. 2012;59:703–710. doi: 10.1016/j.jacc.2011.09.069.
- Vassileva CM, Shabosky J, Boley T, Markwell S, Hazelrigg S. Tricuspid valve surgery: the past 10 years from the Nationwide Inpatient Sample (NIS) database. *J Thorac Cardiovasc Surg*. 2012;143:1043–1049. doi: 10.1016/j.jtcvs.2011.07.004.
- Varadarajan P, Pai RG. Tricuspid regurgitation in patients with severe mitral regurgitation and normal left ventricular ejection fraction: risk factors and prognostic implications in a cohort of 895 patients. *J Heart Valve Dis*. 2010;19:412–419.
- Lauten A, Ferrari M, Goebel B, Rademacher W, Schumm J, Uth O, Kiehltopf M, Figulla HR, Jung C. Microvascular tissue perfusion is impaired in acutely decompensated heart failure and improves following standard treatment. *Eur J Heart Fail*. 2011;13:711–717. doi: 10.1093/eurjhf/hfr043.
- Nickenig G, Kowalski M, Hausleiter J, Braun D, Schofer J, Yzeiraj E, Rudolph V, Friedrichs K, Maisano F, Taramasso M, Fam N, Bianchi G, Bedogni F, Denti P, Alfieri O, Latib A, Colombo A, Hammerstingl C, Schueler R. Transcatheter treatment of severe tricuspid regurgitation with the edge-to-edge MitraClip technique. *Circulation*. 2017;135:1802–1814. doi: 10.1161/CIRCULATIONAHA.116.024848.
- Lauten A, Figulla HR, Willich C, Jung C, Rademacher W, Schubert H, Ferrari M. Heterotopic valve replacement as an interventional approach to tricuspid regurgitation. *J Am Coll Cardiol*. 2010;55:499–500. doi: 10.1016/j.jacc.2009.09.034.
- Rodés-Cabau J, Hahn RT, Latib A, Laule M, Lauten A, Maisano F, Schofer J, Campelo-Parada F, Puri R, Vahanian A. Transcatheter therapies for treating tricuspid regurgitation. *J Am Coll Cardiol*. 2016;67:1829–1845. doi: 10.1016/j.jacc.2016.01.063.
- Figulla HR, Webb JG, Lauten A, Feldman T. The transcatheter valve technology pipeline for treatment of adult valvular heart disease. *Eur Heart J*. 2016;37:2226–2239. doi: 10.1093/eurheartj/ehw153.
- Lichtenauer M, Goebel B, Fritzenwanger M, Förster M, Betge S, Lauten A, Figulla HR, Jung C. Simulated temporary hypoxia triggers the release of CD31+/Annexin+ endothelial microparticles: a prospective pilot study in humans. *Clin Hemorheol Microcirc*. 2015;61:83–90. doi: 10.3233/CH-141908.
- Rosser BA, Taramasso M, Maisano F. Transcatheter interventions for tricuspid regurgitation: TriCinch (4Tech). *EuroIntervention*. 2016;12:Y110–Y112. doi: 10.4244/EIJV12SYA30.
- Taramasso M, Nietlispach F, Zuber M, Maisano F. Transcatheter repair of persistent tricuspid regurgitation after MitraClip with the TriCinch system: interventional valve treatment toward the surgical standard. *Eur Heart J*. 2017;38:1259. doi: 10.1093/eurheartj/ehw541.
- Lausberg HF, Grysckiewicz R, Kuetting M, Baumgaertner M, Centola M, Wendel HP, Nowak-Machen M, Schibilsky D, Kruger T, Schlensak C. Catheter-based tricuspid valve replacement: first experimental data of a newly designed bileaflet stent graft prosthesis. *Eur J Cardiothorac Surg*. 2017;52:189–196. doi: 10.1093/ejcts/ezx084.
- Lauten A, Figulla HR, Willich C, Laube A, Rademacher W, Schubert H, Bischoff S, Ferrari M. Percutaneous caval stent valve implantation: investigation of an interventional approach for treatment of tricuspid regurgitation. *Eur Heart J*. 2010;31:1274–1281. doi: 10.1093/eurheartj/ehp474.
- Lauten A, Laube A, Schubert H, Bischoff S, Nietzsche S, Horstkötter K, Poudel-Bochmann B, Franz M, Lichtenberg A, Figulla HR, Akhyari P. Transcatheter treatment of tricuspid regurgitation by caval valve implantation—experimental evaluation of decellularized tissue valves in central venous position. *Catheter Cardiovasc Interv*. 2015;85:150–160. doi: 10.1002/ccd.25380.
- Lauten A, Ferrari M, Hekmat K, Pfeifer R, Dannberg G, Ragošchke-Schumm A, Figulla HR. Heterotopic transcatheter tricuspid valve implantation: first-in-man application of a novel approach to tricuspid regurgitation. *Eur Heart J*. 2011;32:1207–1213. doi: 10.1093/eurheartj/ehr028.
- Laule M, Stangl V, Sanad W, Lembcke A, Baumann G, Stangl K. Percutaneous transfemoral management of severe secondary tricuspid regurgitation with Edwards Sapien XT bioprosthesis: first-in-man experience. *J Am Coll Cardiol*. 2013;61:1929–1931. doi: 10.1016/j.jacc.2013.01.070.
- Duerr GD, Endlich M, Sinning JM, Esmailzadeh B, Werner N, Mellert F. Surgical banding of the inferior vena cava for the facilitation of transcatheter valve implantation in a patient with severe secondary tricuspid regurgitation. *Eur Heart J*. 2014;35:2839–2849. doi: 10.1093/eurheartj/ehu521.
- Hoepfer MM, Bogaard HJ, Condliffe R, Frantz R, Khanna D, Kurzyna M, Langleben D, Manes A, Satoh T, Torres F, Wilkins MR, Badesch DB. Definitions and diagnosis of pulmonary hypertension. *J Am Coll Cardiol*. 2013;62(25 suppl):D42–D50. doi: 10.1016/j.jacc.2013.10.032.
- Schueler R, Hammerstingl C, Werner N, Nickenig G. Interventional direct annuloplasty for functional tricuspid regurgitation. *JACC Cardiovasc Interv*. 2017;10:415–416. doi: 10.1016/j.jcin.2016.10.033.
- Schueler R, Öztürk C, Sinning JM, Werner N, Welz A, Hammerstingl C, Nickenig G. Impact of baseline tricuspid regurgitation on long-term clinical outcomes and survival after interventional edge-to-edge repair for mitral regurgitation. *Clin Res Cardiol*. 2017;106:350–358. doi: 10.1007/s00392-016-1062-1.
- Campelo-Parada F, Perlman G, Philippon F, Ye J, Thompson C, Bédard E, Abdul-Jawad Altisent O, Del Trigo M, Leipsic J, Blanke P, Dvir D, Puri R, Webb JG, Rodés-Cabau J. First-in-man experience of a novel transcatheter repair system for treating severe tricuspid regurgitation. *J Am Coll Cardiol*. 2015;66:2475–2483. doi: 10.1016/j.jacc.2015.09.068.
- Schofer J, Bijklic K, Tiburtius C, Hansen L, Groothuis A, Hahn RT. First-in-human transcatheter tricuspid valve repair in a patient with severely regurgitant tricuspid valve. *J Am Coll Cardiol*. 2015;65:1190–1195. doi: 10.1016/j.jacc.2015.01.025.
- Lauten A, Doenst T, Hamadanchi A, Franz M, Figulla HR. Percutaneous bivalvular valve implantation for transcatheter treatment of tricuspid regurgitation: clinical observations and 12-month follow-up. *Circ Cardiovasc Interv*. 2014;7:268–272. doi: 10.1161/CIRCINTERVENTIONS.113.001033.

Interventional Treatment of Severe Tricuspid Regurgitation: Early Clinical Experience in a Multicenter, Observational, First-in-Man Study

Alexander Lauten, Hans R. Figulla, Axel Unbehaun, Neil Fam, Joachim Schofer, Torsten Doenst, Joerg Hausleiter, Marcus Franz, Christian Jung, Henryk Dreger, David Leistner, Brunilda Alushi, Anja Stundl, Ulf Landmesser, Volkmar Falk, Karl Stangl and Michael Laule

Circ Cardiovasc Interv. 2018;11:

doi: 10.1161/CIRCINTERVENTIONS.117.006061

Circulation: Cardiovascular Interventions is published by the American Heart Association, 7272 Greenville Avenue, Dallas, TX 75231

Copyright © 2018 American Heart Association, Inc. All rights reserved.

Print ISSN: 1941-7640. Online ISSN: 1941-7632

The online version of this article, along with updated information and services, is located on the World Wide Web at:

<http://circinterventions.ahajournals.org/content/11/2/e006061>

Data Supplement (unedited) at:

<http://circinterventions.ahajournals.org/content/suppl/2018/02/15/CIRCINTERVENTIONS.117.006061.DC1>

Permissions: Requests for permissions to reproduce figures, tables, or portions of articles originally published in *Circulation: Cardiovascular Interventions* can be obtained via RightsLink, a service of the Copyright Clearance Center, not the Editorial Office. Once the online version of the published article for which permission is being requested is located, click Request Permissions in the middle column of the Web page under Services. Further information about this process is available in the [Permissions and Rights Question and Answer](#) document.

Reprints: Information about reprints can be found online at:
<http://www.lww.com/reprints>

Subscriptions: Information about subscribing to *Circulation: Cardiovascular Interventions* is online at:
<http://circinterventions.ahajournals.org/subscriptions/>

Online supplement – Video 1:

Implantation procedure guided by fluoroscopy and transesophageal echo.